



PRESENTING CLINICAL SIGNS

DATE History: Owner came home yesterday and found Lois laying in bed with a wet spot. She seemed disoriented, leapt out of bed, and was ataxic. Lois was biting at her tongue and her owner's hand. Seizure suspected but want to ruled out cardiovascular cause. Transitioning from a grain-free diet. BP WNL.

7/29/22

ECHOCARDIOGRAPHIC FINDINGS

PERFORMED BY: 2D, M-mode, and Doppler study.

Dr. Kelly Romero

Left atrial size is normal. The mitral valve is normal. Left ventricular dimensions are normal, as is left ventricular systolic function. The aorta and aortic valve are normal. Right atrial and right ventricular dimensions are normal. The tricuspid valve is normal. The pulmonary artery and pulmonic valve are normal. No shunting lesions are visualized. No pericardial effusion or cardiac masses are seen.

INTERPRETED BY

Keith Blass, DVM, MS, DACVIM (Cardiology)

LA - 30.9 mm
LVIDd - 33.5 mm
LVIDs - 24.0 mm
FS - 28.4%
RA - 23.2 mm
LVOT - 1.12 m/s
RVOT - 0.77 m/s

PATIENT

Lois Dame

SPECIES

Canine

ASSESSMENT/RECOMMENDATIONS

Normal echocardiogram

This examination demonstrates no evidence of structural heart disease. As such, no reason for Lois' seizure-like episode is appreciated in the image set, though an intermittent arrhythmia cannot be definitively ruled out as a possible cause.

BREED

Border Collie

No therapy is recommended based on this exam.

SEX

A Holter and/or event monitor may be warranted if Lois experiencing additional seizure-like episodes. A recheck echocardiogram is recommended if new physical exam and/or clinical abnormalities suggestive of the presence of structural heart disease develop.

FS

AGE

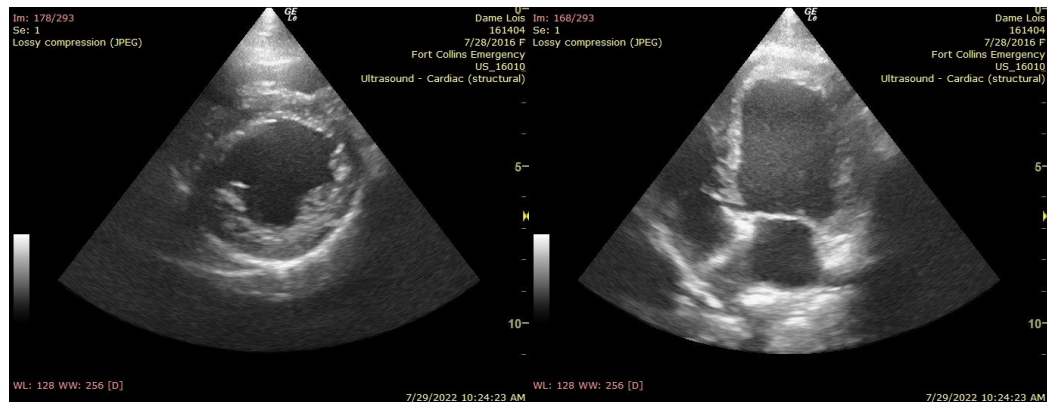
6 y

WEIGHT

19.8 kg

HOSPITAL NAME

Fort Collins Emergency Hospital



REFERRING VET

Dr. Romero

The information and recommendations provided are based on the images presented by the referring veterinarian. No evaluation can be communicated regarding pathology that was not



visible in the image/video clips provided.

DATE

7/29/22

Thank you for this referral. If the clinical or image interpretation does not parallel your findings or if I can be of any further assistance please contact me.

PERFORMED BY: Keith Blass, DVM, MS, DACVIM (Cardiology)
KeithBlass@gmail.com
631-804-5754

Dr. Kelly Romero

INTERPRETED BY

Keith Blass, DVM,
MS, DACVIM
(Cardiology)

PATIENT

Lois Dame

SPECIES

Canine

BREED

Border Collie

SEX

FS

AGE

6 y

WEIGHT

19.8 kg

HOSPITAL NAME

Fort Collins
Emergency Hospital

REFERRING VET

Dr. Romero